

An Unusual Abdominal Mass

Lisi G¹, Greco R², Trotta D³ and Aricò M⁴

¹Pediatric Surgery, Gabriele d'Annunzio University of Chieti and Pescara, Department of Sciences

²Pediatrics, Ospedale Civile, A.S.L. Pescara, Italy

³Pediatrics, Ospedale Civile, A.S.L. Pescara, Italy

⁴Pediatrics, Ospedale Civile, A.S.L. Pescara, Italy

***Corresponding author:** Maurizio Aricò, Pediatrics, Ospedale Civile, A.S.L. Pescara, Italy

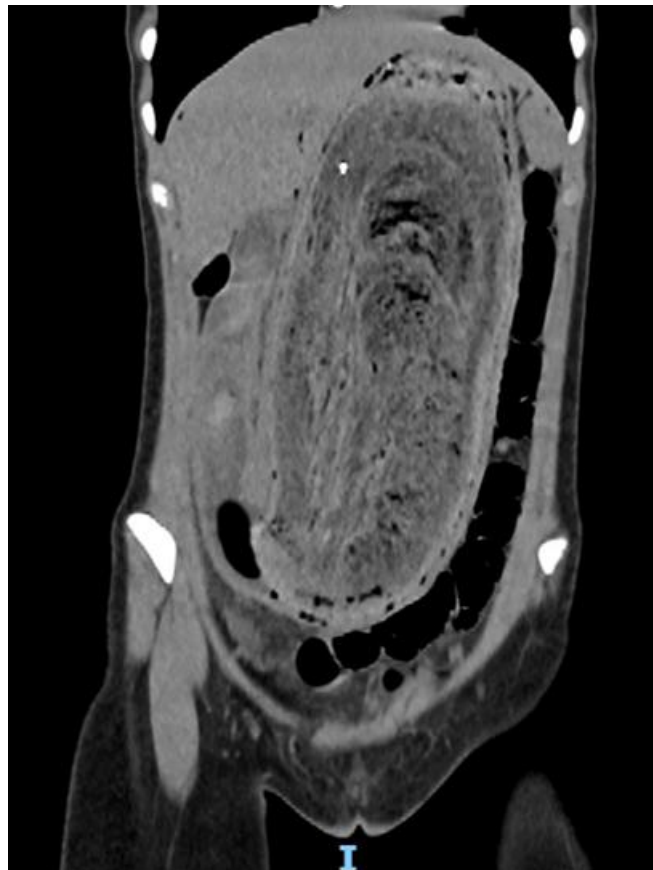
Copyright: Maurizio Aricò, This article is freely available under the Creative Commons Attribution License, allowing unrestricted use, distribution, and non-commercial building upon your work.

Citation: Maurizio Aricò, An Unusual Abdominal Mass, Ann Med Clin Cas Rept, 2025; 1(2): 1-2.

Published Date: 20-03-2025 **Accepted Date:** 14-03-2025 **Received Date:** 06-03-2025

Case Report

A 15-year female came for abdominal pain during the last three days, diarrhea during the last 24 hours. Nausea during the last month but not vomiting. Menses were usually regular, with the only exception of the month before. Allergic to dried fruit, banana and egg. Routine lab work-up was non-informative as well as abdominal US. Thus abdominal CT scan was performed. 28 cm x 8.8 cm su RM.



The CT scan was strongly suggestive for bezoar. The girl underwent immediate open surgery, with removal from the stomach of a mass sized 46 cm. in length and 12 cm. in maximum thickness, in practice a cast of the esophageal-gastric tract.

Removal was uneventful and the child, on day +15 from surgery, could be discharged.

To a targeted anamnesis, the girl and her mother reported her habit of swallowing her hairs (“trichotillomania”) but also bird feather or pencil fragments. Psychological support was advised.

