

## Evaluation of Pink Esthetic Score in Flapless Molar Implant Rehabilitation

**Mahesh L\***

Implantologist, Private Practice, Lanka Mahesh Implantologist, Private Practice, The Dental Centre, India

\***Corresponding author:** Lanka Mahesh, Implantologist, Private Practice, Lanka Mahesh Implantologist, Private Practice, The Dental Centre, S-382, Panshila Prak, New Delhi-110017, India

**Copyright:** Lanka Mahesh, This article is freely available under the Creative Commons Attribution License, allowing unrestricted use, distribution, and non-commercial building upon your work.

**Citation:** Lanka Mahesh, Evaluation of Pink Esthetic Score in Flapless Molar Implant Rehabilitation, Ann Oral Sci, 2024; 1(1): 1-6.

**Published Date:** 06-08-2024 **Accepted Date:** 01-08-2024 **Received Date:** 21-07-2024

**Keywords:** Flapless Implant; Single stage surgery; Pink EstheticScore

### Abstract:

**Statement of Problem:** Pink Esthetic Score has established its reliability in Objective assessment of esthetics till premolars. However its application to implant prosthesis replacing molars placed by flapless technique needs to be evaluated especially for patients having a wide smile.

**Purpose:** This study aims to assess the Pink Esthetic Score for single Implant crowns in the region of mandibular first molars.

**Material and Methods:** 20 single implant crowns in mandibular first molar region were evaluated for Pink Esthetic Score using 7 evaluation criteria 6 months post rehabilitation.

**Results:** The mean PES value obtained after evaluating 20 images from 20 patients was  $12.9 \pm 2.37$ . The alveolar process deficiency ( $2.00 \pm 0.00$ ) had highest score and distal papilla the lowest ( $1.55 \pm 0.69$ ).

**Conclusions:** Flapless implants with single implant crowns in molars placed in optimal conditions lead to a favorable esthetic outcome in terms of PES value.

**Clinical Implication:** A carefully selected posterior implant sites for flapless implant placement which should be free of any alveolar bone deficiency, having Division a bone type and adequate interocclusal space leads to an esthetically pleasing posterior implant restoration.

### 1. Introduction

With the progress in modern day implantology, the implant success criteria gradually shifted from just survival rates to optimal esthetics [1]. To objectively quantify esthetics, Furhauser in 2005 published the Pink Esthetic Score [2]. With the passing years PES established itself as a gold standard in objectively assessing single implants esthetics. Seven soft tissue parameters are assessed: the mesial and distal papilla, contour, margin level, alveolar process deficiency, mucosal colour and texture. For each one of the seven variables a 2-1-0 score is assessed, with 2 being the best and 0 being the poorest score [2] (Table 1).

**Table 1:** Modified pink esthetic score (PES after Fürhauser et al.)

	0	1	2
Mesial papilla	Absent	Incomplete	Complete
Distal papilla	Absent	Incomplete	Complete
Soft tissue level	Major discrepancy >2 mm	Minor discrepancy 1 mm	No discrepancy 0 mm
Soft tissue contour	Unnatural	Fairly natural	Natural
Alveolar crest deficit	Obvious	Slight	None
Soft tissue color	Obvious difference	Moderate difference	No difference
Soft tissue texture	Obvious difference	Moderate difference	No difference

Most of the studies involving PES evaluate the score in anterior maxilla or upto the premolars. However, these esthetic parameters are also of pertinent importance in posterior areas. If these parameters are not fulfilled these can create place for food entrapment leading to periimplant mucositis and eventually periimplantitis.

The objective of the current article is to show the results of PES of 20 flapless single molar implants.

## 2. Material and Methods

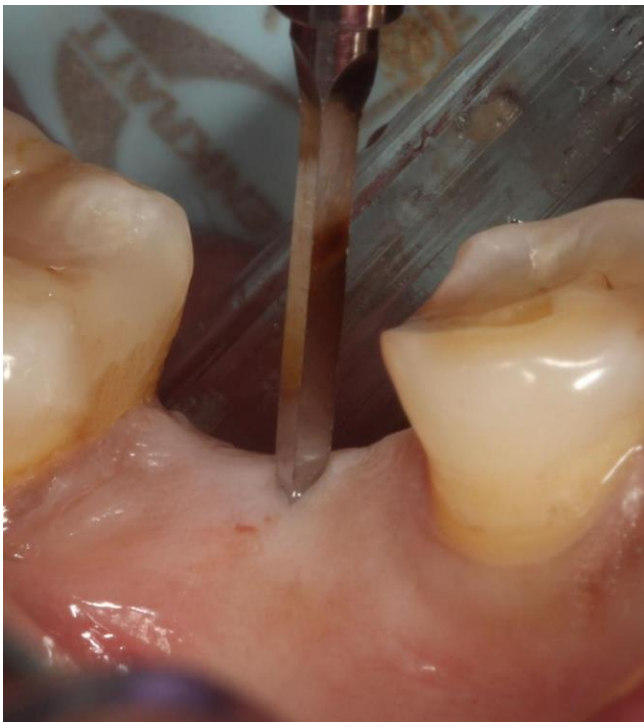
20 Patients with single missing mandibular first molars (14 males and 06 females) were selected with a minimum age of 22 years and maximum age of 56 years. The mean age of the patients was 38 years. The Inclusion criteria were:

- Division A bone with interocclusal space 7 mm or more.
- Thick gingival phenotype.
- Absence of any tilting of the adjacent teeth.
- Tooth loss not over 6 months.

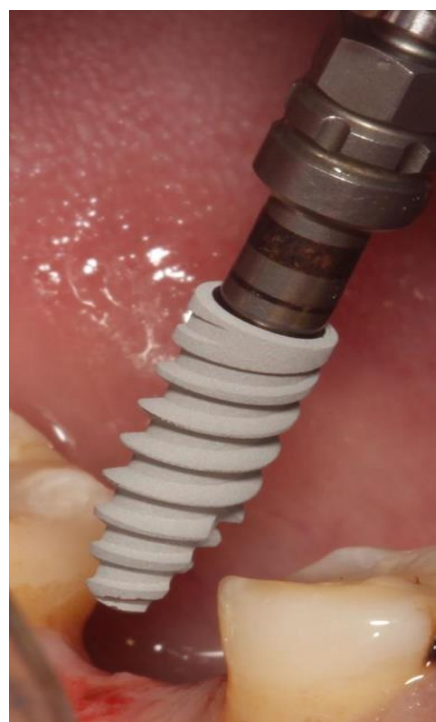Implants of 4.0mm or 5.0mm width (Bioner Top DM, Spain) and optimal lengths were placed in the sites as planned on CBCT. Implant osteotomies were prepared without raising a flap via punch (Figure 1). Implants were placed 0.5 to 1mm subcrestally (Figure 2) and a transmucosal healing protocol was followed. Healing abutments flush with soft tissue were placed to avoid the need for a stage 2 surgery after 3months (Figure 3). Post-operative IOPA X rays were taken (Figure 4).

Restorative phase was initiated after 3 months. The healing abutment was removed and epithelial cuff was evaluated (Figure 5). An intraoral scan (Trios 3, 3 Shapes) of the entire arch was done without the healing abutment followed by a placement of a scan body and another scan of the arch. The scan body was verified for the fit via an intraoral periapical X ray. The opposing arch and bite were also captured digitally.

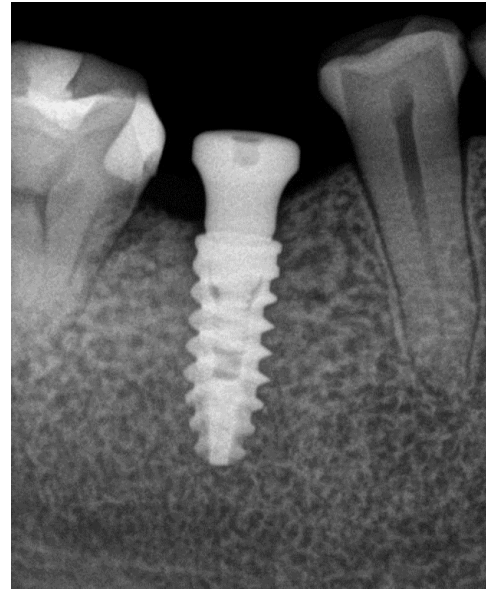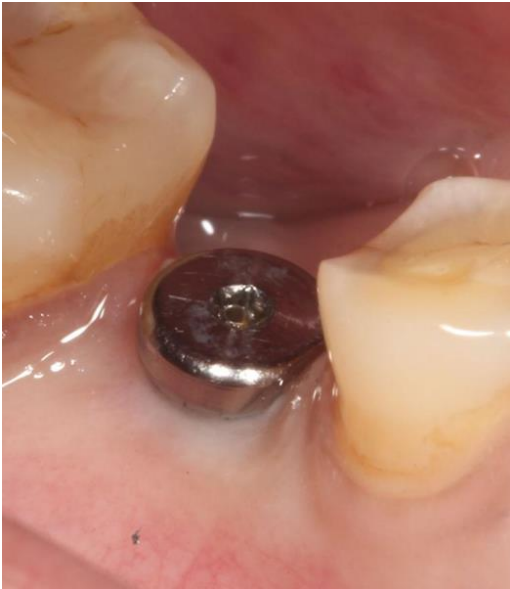Premilled titanium abutments were used to mill the desired abutment profile and a CAD PFM crown was fabricated over it (Figure 6). The cementation was done using a resin cement (3M RelyX U200). The entire prosthesis was tried and torqued with a calibrated torque wrench to 30 N cm into the patients' mouth and PES was evaluated at 6 months recall visit. (Figure 7). Iopa X rays at the time of PES evaluation were taken (Figure 8).



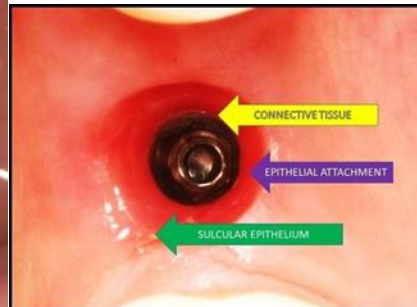
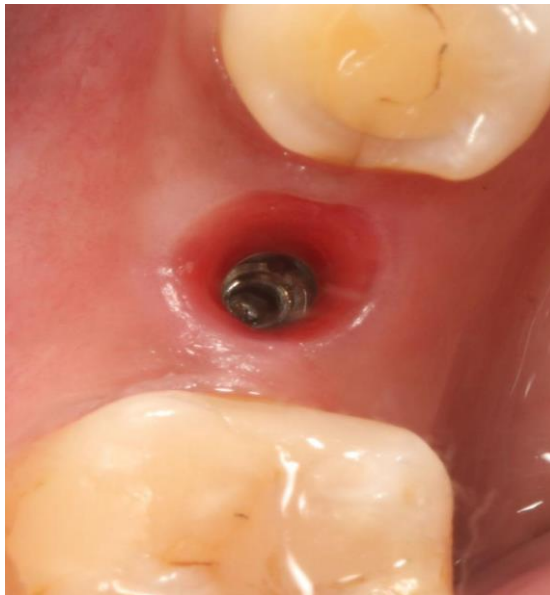**Figure 1:** Implant osteotomy via transmucosal approach



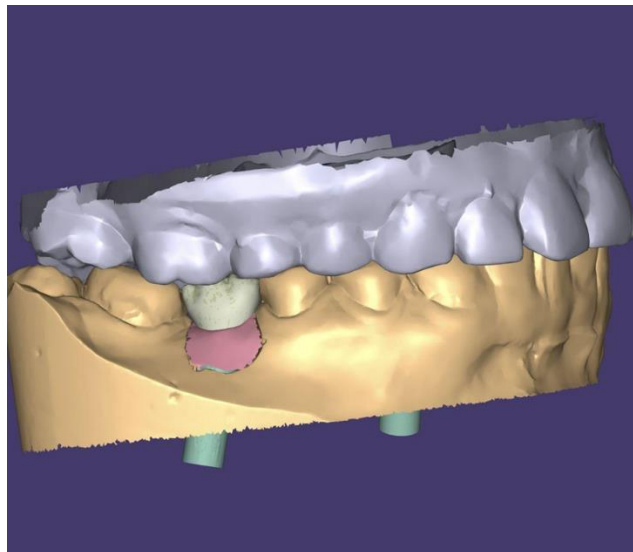
**Figure 2:** Implant placed via tranmucosal approach



**Figure 3:** Healing abutment along with implant placement **Figure 4:** Post placement X ray of Implant with healing abutment



**Figure 5:** Healed epithelia cuff with description



**Figure 6:** CAD CAM design of Implant Crown

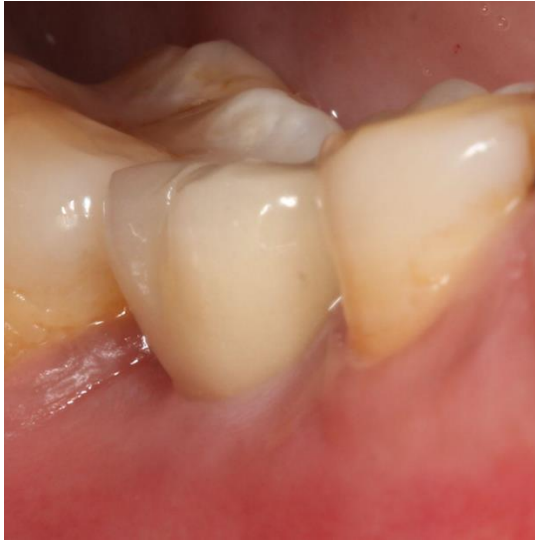

Figure 7: PES evaluation at 6 months

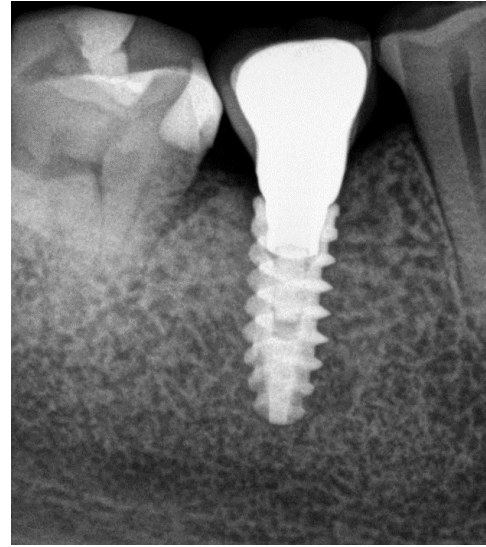


Figure 8: IOPA X ray at the time of PES evaluation

### 3. Results

#### 3.1. Evaluation of PES

All parameters of Pink Esthetic Score were evaluated over score of 0 to 2 with 0 indicating large discrepancy and score of 2 depicting high resemblance to the **adjacent molar**. Intraoral photographs were taken at all visits using Digital CANON EOS 3000D SLR camera with Macro lens (Canon EF 100mm F/2.8 Macro USM Prime lens for Canon SLR). All photographs were standardized by framing the adjacent tooth under same lighting conditions (Canon Macro Ring Flash/ LED Macro Flash Speedlite with 2PCS Flash Head). Images were analyzed on a 40 inches LG screen by the same assessor [3].

**Table 2:** Total PES values measurede = 12.9±2.37

PES CRITERIA (N=20)	Mesial Papilla	Distal Papilla	Height of Gingival Margin	Soft tissue Contour	Alveolar process deficiency	Colour	Texture
1	2	2	2	2	2	2	2
2	2	2	2	2	2	2	2
3	2	2	2	2	2	2	2
4	1	0	1	1	2	1	2
5	2	2	2	2	2	2	2
6	2	2	2	2	2	2	2
7	1	1	2	2	2	2	2
8	2	2	2	2	2	2	2
9	2	2	2	2	2	2	2
10	2	1	2	2	2	2	2
11	1	1	2	2	2	2	2
12	2	1	2	2	2	2	2
13	1	1	2	2	2	2	2
14	2	2	2	2	2	2	2
15	2	2	2	2	2	2	2
16	2	2	2	2	2	2	1
17	2	2	2	2	2	2	2
18	2	2	2	2	2	2	2
19	1	0	1	1	2	1	1
20	2	2	2	2	2	2	2
<b>Mean</b>	<b>1.75</b>	<b>1.55</b>	<b>1.9</b>	<b>1.9</b>	<b>2</b>	<b>1.9</b>	<b>1.9</b>
<b>SD</b>	<b>0.44</b>	<b>0.69</b>	<b>0.31</b>	<b>0.31</b>	<b>0</b>	<b>0.31</b>	<b>0.31</b>



### 3. Discussion

The PES found in our study ( $12.3 \pm 2.37$ ) for molar evaluation was higher as compared to the values reported in literature for anterior teeth ( $8.63 \pm 2.4$ ).

Wipawin et al [4]. carried out a prospective study to analyze the PES in 25 single implants restored with a screw-cement retained single crown on a titanium-based abutment. The authors reported a mean mPES score was  $9.75 \pm 0.44$  (range: 9–10 score).

For their part, Edinger and Euer [5] analyzed 26 implants placed in 22 patients and obtained a maximum PES value of 14. Of these implants, five were placed in the anterior region, 9 in the premolar, and 12 in the molar region.

Hurtgen et al [6]. reported the following PES values:  $9.55 \pm 2.58$  in implants with triangular neck while  $9.64 \pm 1.55$  in the group of implants with circular neck. (PES3)

The existent literature [7] has reported a prevalence of peri-implantitis 10% on the implant level and 20% on the patient level after a follow-up period of varying from 5 to 10 years.

Li Manni et al [8]. carried out a randomized controlled trial to compare traditional and triangular neck study over 32 patients that needed the replacement of a single hopeless tooth in the posterior maxilla. Two different types of implants were inserted (triangular neck and circular neck). PES values were  $11.3 \pm 2.4$  for Triangular neck group vs.  $10.7 \pm 1.8$  for Circular neck group; ( $p = .44$ ). The authors concluded that the implant neck design did not impact the pink aesthetic score and the patient satisfaction.

The highly favorable PES obtained in the present study may be attributed to the strict inclusion criteria of thick gingival biotype, Division A bone and no tilting of the adjacent teeth. These findings were also reported by Cosyn et al. in their study where sample selection criteria were thick gingival phenotype and no bone defect [9].

As far as the restorative material choice is concerned, no statistically significant differences were found between all ceramic crowns and metal fused to ceramic crowns [10]. No statistically significant difference was also noted by the usage of Metal versus ceramic abutments [11]. However, cement retained restorations may pose a challenge towards cement induced periimplantitis. In our study, premilled titanium abutments were used so that the implant to abutments connection retains the precision. The CAD PFM crown fabricated has a screw access hole for retrievability and cementation was done extra orally so no excess cement remains. Thus, no situation of cement induced periimplantitis arose in our study.

Any implant restoration whether in anterior or posterior zone should serve all three rehabilitation goals- form, function and esthetics. Esthetic concerns if not addressed in posterior implant rehabilitations can lead to future complications.

### 4. Conclusions

Flapless posterior implant placement and digital rehabilitation can lead to a favorable result of PES if case selection has favorable criteria.

### References

1. Smith DE, Zarb GA. Criteria for success of osseointegrated implants. *J Prosthet Dent.* 1989; 62: 567-72.
2. Furhauer R, Florescu D, Benesch T, Haas R, Mailath G, Watzek G. Evaluation of soft tissue around single-tooth implant crown: the pink esthetic score. *Clin Oral Impl Res.* 2005; 16: 639-44.
3. Vidigal GM, Groisman M, Clavijo VGR, Santos IGBP, Fischer RG. Evaluation of Pink and White Esthetic Score for immediately placed and provisionally restored implants in anterior maxilla. *Int J Oral Maxillofac Implants* 2017; 32: 625-32.
4. Wipawin R, Amornsettachai P, Panyayong W, Rokaya D, Thiradilok S, Pujarern P, Suphangul S. Clinical outcomes of 3-5 years follow-up of immediate implant placement in posterior teeth: a prospective study. *BMC Oral Health.* 2024; 24(1): 312.
5. Edinger DH, Beuer F. Rehabilitation of one-piece screw-retained implant crowns placed at second-stage surgery-a retrospective patient series. *Clin Oral Investig.* 2021; 25(3): 1345-51.
6. Hurtgen A, Seidel L, Manni LL, Liegeois L, Lecloux G, Lambert F. Clinical and radiographic assessment of circular versus triangular cross-section neck implants in the posterior maxilla: Five-year follow-up of a randomized controlled trial. *Clin Oral Implants Res.* 2023; 34(7): 698-706.

7. Mombelli A, Müller N, Cionca N. (The epidemiology of peri-implantitis. *Clin Oral Impl Res.* 2012; 23(Suppl 6); 67-76.
8. Li Manni L, Lecloux G, Rompen E, Aouini W, Shapira L, Lambert F. Clinical and radiographic assessment of circular versus triangular cross-section neck Implants in the posterior maxilla: A 1-year randomized controlled trial. *Clin Oral Implants Res.* 2020; 31(9): 814-24.
9. Cosyn J, Eghbali A, De Bruyn DE, Dierens M, De Rouck T. Single implant treatment in healing versus healed sites of anterior maxilla: An esthetic evaluation. *Clin Implant Dent Relat Res.* 2012; 14: 517-26.
10. Gallucci GO, Grutter L, Nedir R, Bischof M, Belser UC. Esthetic outcomes with porcelain-fused-to-metal and all-ceramic single-implant crowns: A arandomised clinical trial. *Clin Oral Implants Res.* 2011; 22: 62-9.
11. Vanlioglu BA, Kahramanoglu E, Yildiz C, Ozkan Y, Kulak-Ozkan Y. Esthetic outcome evaluation of maxillary anterior single-tooth bone-level implants with metal or ceramic abutments and ceramic crowns. *Int J Oral Maxillofac Implants.* 2014; 29: 1130-6.